

Traumatic Rupture of the Ligamentum Teres as a Source of Hip Pain

J. W. Thomas Byrd, M.D., and Kay S. Jones, M.S.N., R.N.

Purpose: Lesions of the ligamentum teres have only occasionally been reported in the literature. However, with arthroscopy, pathology of the ligamentum teres has been increasingly recognized. The purpose of this article is to report the clinical characteristics associated with rupture of the ligamentum teres and the results of arthroscopic treatment. **Type of Study:** Case series study. **Methods:** All patients undergoing hip arthroscopy have been prospectively assessed using a modified Harris Hip score (100 point maximum) obtained preoperatively and postoperatively at 3, 12, 24, and 60 months. In this study, 271 cases had at least 1 year of follow-up evaluation. From this population, 41 patients were identified with lesions of the ligamentum teres. Twenty-three of these were traumatic in origin and represent the substance of this study. The remainder (18) were hypertrophic or degenerative. **Results:** We noted 100% follow-up at an average of 29.2 months. Patients included 14 women and 9 men with an average age of 28.3 years. Duration of symptoms before surgery averaged 28.5 months. All patients experienced deep anterior groin pain. Nineteen patients experienced mechanical symptoms (catching, popping, locking, giving way), and 4 patients described simply pain with activities. Fifteen patients sustained major trauma (7 motor vehicle accidents, 3 falls from a height, 3 football, 1 snow skiing, 1 ice hockey), including 6 dislocations. The remaining 8 patients sustained a twisting injury. Evaluation included 20 magnetic resonance imaging (MRI) scans, 7 MR arthrograms, 7 computed tomography (CT) scans, and 3 bone scans. The diagnosis of a lesion of the ligamentum teres was made preoperatively in only 2 cases. Rupture of the ligament was complete in 12 cases and partial in 11. Ligament injury was an isolated finding in 8 cases, and associated pathology was found in 15 cases (9 labral tears, 5 loose bodies, 5 chondral damage). The average preoperative score was 47, and postoperative score was 90. No statistical difference was seen based on type of injury, complete versus partial rupture, or presence of coexistent pathology. **Conclusions:** Rupture of the ligamentum teres is increasingly recognized as a source of persistent hip pain. The diagnosis remains elusive to various imaging techniques. An index of suspicion should be maintained, especially in the presence of mechanical symptoms and a history of significant trauma. However, rupture may occur simply from a twisting injury in absence of major trauma. These lesions can be diagnosed using arthroscopy and, based on these results, may respond remarkably well to arthroscopic debridement. **Level of Evidence:** Level IV. **Key Words:** Hip arthroscopy—Ligamentum teres—Hip pain—Results.

Damage to the ligamentum teres has rarely been reported as a cause of hip pain. Rupture is known to occur with dislocation of the joint, but disruption in

absence of a dislocation has been described in the literature in only a few isolated case reports.¹⁻⁴

Literature reflecting clinical experiences in hip arthroscopy began to flourish early in the last decade. Within these reports, damage to the ligamentum teres was not mentioned as an observation or indication for performing the procedure.^{5,6} Only McCarthy et al.⁷ even referenced the ligament, stating that it was unknown whether an injury to the structure could cause pain. In 1997, Gray and Villar⁸ described and classified lesions of the ligamentum teres. Since then, this injury has been noted as an indication for arthroscopy, and an additional case report has been published.^{9,10}

From the Nashville Sports Medicine & Orthopaedic Center, Department of Orthopaedics and Rehabilitation (J.W.T.B.K.S.J.), and Vanderbilt University School of Medicine (J.W.T.B.) Nashville, Tennessee, U.S.A.

Address correspondence and reprint requests to J. W. Thomas Byrd, M.D., Nashville Sports Medicine & Orthopaedic Center, 2011 Church St, Suite 100, Nashville, TN 37203, U.S.A. E-mail: info@nsmoc.com

*© 2004 by the Arthroscopy Association of North America
0749-8063/04/2004-3629\$30.00/0
doi:10.1016/j.arthro.2004.01.025*

TABLE 1. *Modified Harris Hip Score*

Pain	
44	None/ignores
40	Slight, occasional, no compromise in activity
30	Mild, no effect on ordinary activity, pain after usual activity, uses aspirin
20	Moderate, tolerable, makes concessions, occasional codeine
10	Marked, serious limitations
0	Totally disabled
Function: Gait	
Limp	
11	None
8	Slight
5	Moderate
0	Severe
0	Unable to walk
Support	
11	None
7	Cane, long walks
5	Cane, full time
4	Crutch
2	2 canes
0	2 crutches
0	Unable to walk
Distance Walked	
11	Unlimited
8	6 blocks
5	2-3 blocks
2	Indoors only
0	Bed and chair
Functional Activities	
Stairs	
4	Normally
2	Normally with banister
1	Any method
0	Not able
Sox/Shoes	
4	With ease
2	With difficulty
0	Unable
Sitting	
5	Any chair, 1 hour
3	High chair, 1/2 hour
0	Unable to sit, 1/2 hour, any chair
Public Transportation	
1	Able to enter public transportation
0	Unable to use public transportation
Total Points _____	
Total Score _____	
$\times 1.1$	

NOTE. The Harris hip score includes 91 points for pain and function and 9 points for range of motion and deformity. Arthroscopy is principally indicated for pain and function. Consequently, the section for range of motion and deformity has been deleted. The multiplier (1.1) is used to give a total possible score of 100.

Most recently, we reported our experience with hip arthroscopy in athletes.¹¹ Rupture of the ligamentum teres was the third most common problem encountered and showed one of the best responses to the procedure.

Based on these former studies, we hypothesized that injury to the ligamentum teres is a more significant source of morbidity than was previously recognized. The purpose of this study was to report our experience in the assessment and management of traumatic rupture of the ligamentum teres.

METHODS

All patients undergoing hip arthroscopy are prospectively assessed using a previously published format that includes a modified Harris Hip score (Table 1).¹² Data are obtained preoperatively and then postoperatively at 3, 12, 24, and 60 months. At the time of this report, the database contained 271 consecutive cases with at least 1-year follow-up information. From this population, 41 patients were identified with lesions of the ligamentum teres. A cohort of 23 were traumatic in origin and represent the substance of this study. The remaining 18 were atraumatic, associated

with either degenerative disease or ligament hypertrophy.

All patients were assessed by the senior author (J.W.T.B.), including history, examination, and standard radiographs (anteroposterior pelvis film including both hips and frog lateral of the affected hip). Further investigative studies were not standardized. The majority of patients were referred for treatment, having already undergone various imaging studies. Repeat or adjunct studies were obtained as deemed necessary for the individual clinical circumstances.

The indication for arthroscopy was either intractable hip pain unresponsive to conservative measures or imaging evidence of intra-articular pathology amenable to arthroscopy. All procedures were performed by the senior author using a standard technique previously described.^{5,13} The procedure is performed on an outpatient basis under general anesthesia with the patient positioned supine on a fracture table. Three standard portals (anterior, anterolateral, posterolateral) are used (Figs 1 and 2).

Initially, a systematic inspection of the hip is performed, switching between the 3 established portals and using combinations of the 70° and 30° arthroscopes. The 70° arthroscope provides the best view of the periphery of the acetabulum, labrum, and femoral head and most inferior portion of the acetabular fossa, including the ligamentum teres (Fig 3A). The 30° arthroscope pro-

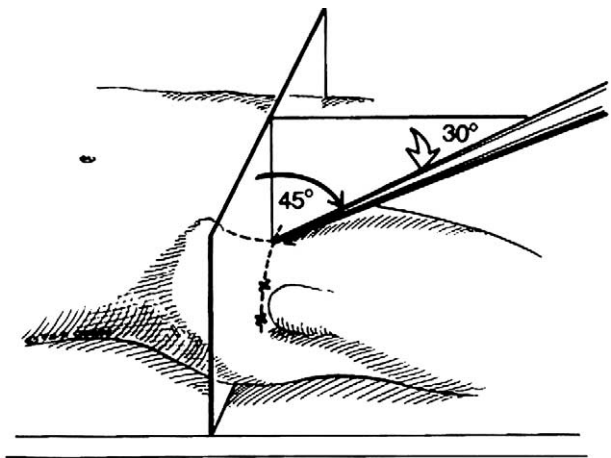


FIGURE 1. The site of the anterior portal coincides with the intersection of a sagittal line drawn distally from the anterosuperior iliac spine and a transverse line across the superior margin of the greater trochanter. The direction of this portal courses approximately 45° cephalad and 30° towards the midline. The anterolateral and posterolateral portals are positioned directly over the superior aspect of the trochanter at its anterior and posterior borders. (Reprinted with permission.⁶)

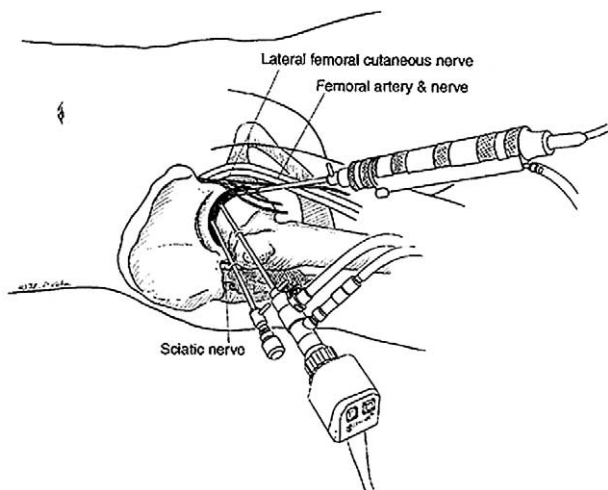


FIGURE 2. The relationship of the major neurovascular structures to the 3 standard portals is shown. The femoral artery and nerve lie well medial to the anterior portal. The sciatic nerve lies posterior to the posterolateral portal. The lateral femoral cutaneous nerve arborizes with small branches lying close to the anterior portal. Injury to this structure is avoided by using proper technique in portal placement.

vides the best view of the central portion of the acetabulum and femoral head and superior part of the fossa.

Coexistent pathology is identified and addressed first, including loose body removal, chondroplasty, and labral excision as necessary. Debridement within the acetabular fossa is performed last because bleeding from this area may transiently interfere with visualization. This is readily managed with hypotensive anesthesia (100 mm Hg systolic blood pressure), addition of epinephrine to the fluid, and cauterization as necessary. Additionally, a high-flow pump is used that allows sufficient flow for optimal visualization without needing increased fluid pressure, which is maintained at 60 mm Hg.

Maneuverability and access within the joint are facilitated by performing small capsular releasing incisions with an arthroscopic knife around the cannula entry sites (Fig 3B). Curved shaver blades are also helpful for reaching the ruptured fibers of the ligamentum teres around the convex surface of the femoral head.

With the arthroscope in the anterolateral portal, the damaged ligament is most readily accessed from the anterior portal (Fig 3C). External rotation of the hip also helps to deliver a portion of the ligament anteriorly for more thorough debridement. The acetabular attachment of the ligamentum teres is more posterior in the inferior aspect of the acetabular fossa, and this portion, when ruptured, is best addressed from the posterolateral portal (Fig 3D).

The disrupted portion of the ligamentum teres is evident as the fibers float freely within the fluid currents created inside the joint (Fig 3A). Thus, these ruptured portions are easily delivered to the shaver blade for debridement by the accompanying suction. Stable portions of the ligament are selectively preserved because they are not brought up to the shaver blade. Indiscriminate debridement of healthy ligament is avoided.

The damaged part of the ligament is relatively avascular, but the pulvinar, consisting of fat pad encased in synovium, resides above it in the superior portion of the acetabular fossa and contains small vessels. In association with underlying injury, the pulvinar tissue may sometimes be dense, contracted, and fibrotic, and other times it is quite proliferative.

Postoperatively, crutches are used for 5 to 7 days until the patient's gait pattern is normalized. Physical therapy is begun on the second postoperative day, emphasizing gentle range of motion, muscle toning, and closed chain exercises as tolerated to regain independence with normal daily activities. Functional drills and return to unrestricted activities are progressed from 1 to 3 months depending on the patient's response and the severity of accompanying pathology.

The following analyses were performed. The preoperative and postoperative scores for the entire group were compared for statistical significance using a 1-sample *t* test. The results of those sustained by violent trauma were compared with twisting injuries; complete ruptures were compared with partial ruptures; and isolated lesions were compared with those with associated pathology. For these comparisons, a multiple regression model was used.

RESULTS

The results are summarized in Table 2. A 100% follow-up rate was seen at an average of 29.2 months (range, 12 to 60 months). Patients included 14 women and 9 men, with an average age of 28.3 years (range, 15 to 53 years).

Fifteen patients sustained violent trauma (7 motor vehicle accidents, 3 falls from a height, 3 football injuries, 1 snow skiing injury, 1 ice hockey injury), including 6 dislocations. The remaining 8 patients sustained a twisting injury. Duration of symptoms before surgery averaged 28.5 months (range, 0.5 to 144 months).

All patients experienced deep anterior groin pain. Nineteen patients experienced mechanical symptoms (catching, popping, locking, giving way), and 4 pa-

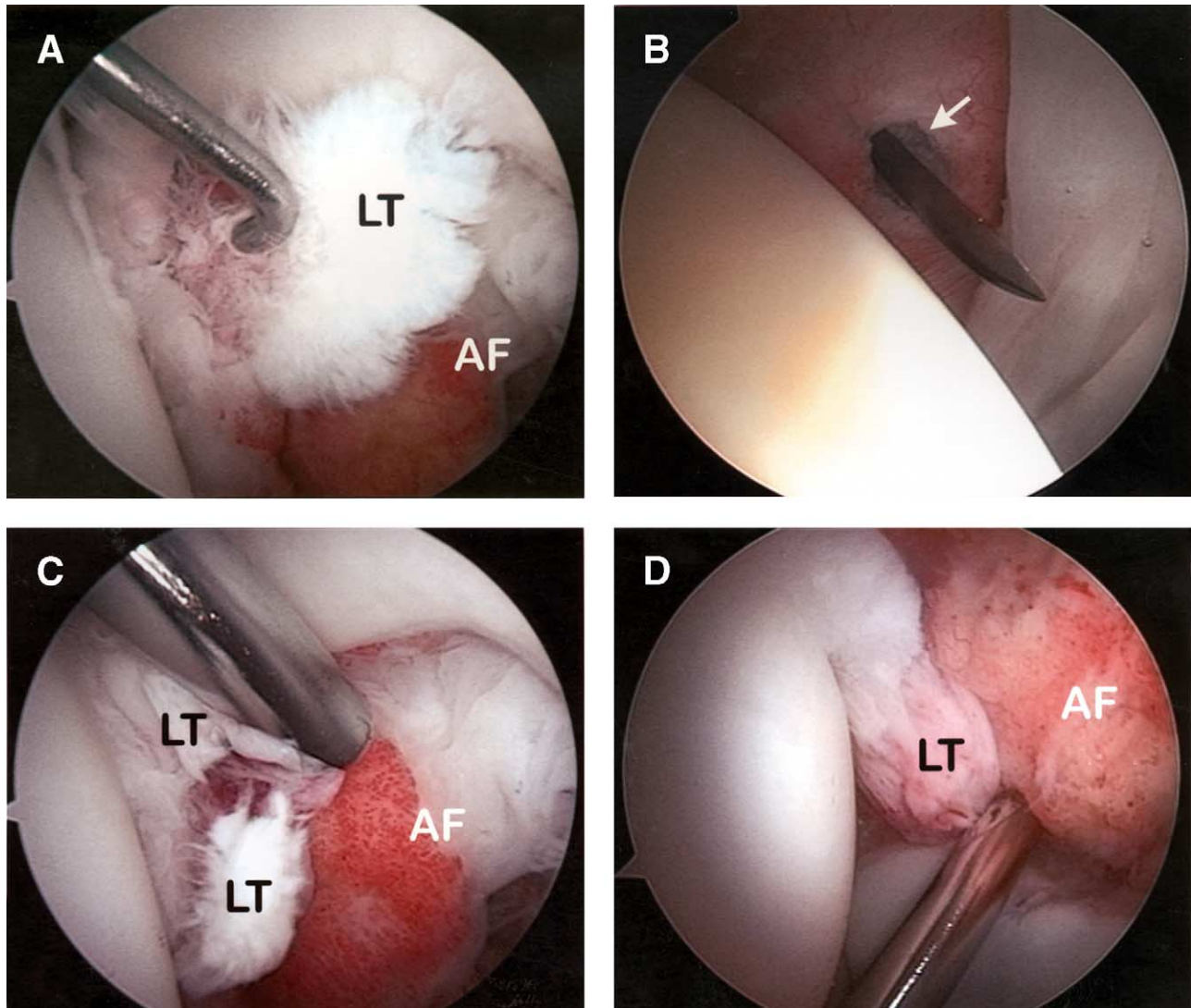


FIGURE 3. View of a right hip from the anterolateral portal with a 70° arthroscope. (A) Rupture of the ligamentum teres (LT) with a probe introduced from the anterior portal, silhouetted by the acetabular fossa (AF) containing the pulvinar tissue. (B) Looking anteriorly, the capsular entry site for the anterior portal (arrow) is being transversely enlarged with an arthroscopic knife. (C) Debridement of the ligamentum teres is most thoroughly accomplished with the shaver from the anterior portal. (D) Debridement of the acetabular attachment in the posterior inferior fossa is best accomplished from the posterolateral portal.

tients described pain with activities. On examination, 15 patients showed pain with log rolling of the hip, and all 23 showed pain with maximal flexion combined with internal rotation. Range of motion was reduced in 6 patients, with an average loss of 24° of rotation. This reduced range of motion was caused by inhibition in 3 patients who had full motion when examined under anesthesia.

All patients were evaluated with plain radiographs. Collectively, these patients also underwent 20 magnetic resonance imaging (MRI) scans, 7 magnetic

resonance arthrograms (MRAs), 7 computed tomography (CT) scans, and 3 radionuclide bone scans. Pathology of the ligamentum teres was identified in only 2 cases by MRA (Fig. 4).

The indication for surgery was intractable hip pain in 9 cases and imaging evidence of intra-articular pathology in 14 cases. At arthroscopy, rupture of the ligament was found to be complete in 12 cases and partial in 11. Ligament injury was an isolated finding in 8 cases, and associated pathology was noted in 15 cases (9 labral tears, 5 loose bodies, 5 chondral damage).

TABLE 2. Summary of Results

Case	Age/ Sex	MOI	DOS (mo)	Symptoms	Studies	Type	Associated Pathology	Results Preop→Postop	F/U (mo)
1	20M	Trauma	26	Pain, popping, locking	MRI	Complete	Chondral damage	15→100	24
2	15F	Trauma	0.5	Pain	CT	Complete	Loose body	26→100	24
3	46M	Trauma	11	Pain, popping, locking	MRI, MRA*	Complete	Labral tear	30→66	12
4	25M	Trauma	6	Pain, catching	CT	Complete	Loose body	51→96	24
5	19F	Trauma	28	Pain, catching	MRI	Complete	Loose body	51→85	60
6	27F	Twisting	7	Pain, catching, locking	MRI × 3 Bone scan	Partial	None	18→96	60
7	22M	Trauma	48	Pain, popping	MRI × 2	Complete	Labral tear, chondral damage, loose body	51→85	24
8	38F	Trauma	20	Pain, catching	MRI	Partial	None	63→62	24
9	44F	Twisting	10	Pain, popping	MRI, MRA	Complete	None	36→96	12
10	35F	Trauma	43	Pain, catching	MRI	Partial	None	54→83	12
11	16M	Trauma	8	Pain, popping	CT	Partial	Chondral damage	57→85	60
12	24M	Trauma	12	Pain, catching, popping	MRA	Complete	Labral tear	51→85	12
13	32F	Twisting	144	Pain, locking	MRA*	Partial	Labral tear	57→100	12
14	21F	Trauma	7	Pain, popping	MRA	Partial	Labral tear	63→100	24
15	29M	Twisting	10	Pain	MRI × 2 Bone scan	Partial	Labral tear	40→61	24
16	45F	Twisting	6	Pain	MRA	Partial	None	63→100	12
17	53F	Trauma	25	Pain, catching, giving way	MRA	Partial	Labral tear	58→96	12
18	29F	Twisting	37	Pain, catching	MRI	Complete	None	61→96	24
19	15F	Twisting	24	Pain	MRI, CT	Complete	None	21→100	60
20	20F	Twisting	10	Pain, popping	MRI × 2	Partial	None	61→96	60
21	27M	Trauma	48	Pain, catching	MRI, CT	Partial	Labral tear	61→96	60
22	17M	Trauma	4	Pain, locking, giving way	MRI, CT Bone scan	Complete	Chondral damage	40→100	24
23	31F	Trauma	120	Pain, catching, locking	MRI, CT	Complete	Labral tear, condral damage, loose body	55→83	12

Abbreviations: MOI, mechanism of injury; DOS, duration of symptoms; MRI, magnetic resonance imaging; MRA, magnetic resonance arthrogram; CT, computed tomogram; F/U = length of follow-up.

*Indicates MRA that identified pathology of ligamentum teres.

Overall, the average preoperative score of 47 improved to 90 postoperatively, which was statistically significant ($P < .001$). Ninety-six percent (22 patients) showed > 20 point improvement. No statistically significant difference was seen between patients with major trauma or twisting injuries, complete or partial ruptures, isolated lesions, or concomitant pathology. One complication occurred—a transient partial neuropraxia of the lateral femoral cutaneous nerve that resolved uneventfully.

DISCUSSION

The normal ligamentum teres is pyramidal in shape, arising from the transverse acetabular ligament and the posterior inferior portion of the acetabular fossa

and attaching to the femoral head at the fovea capitis.¹⁴ Disruption of the ligamentum teres is a known entity. It can be expected in association with dislocation of the hip and can occur without dislocation. However, few cases of this being a direct cause of disability accompanying injury to the hip have been reported.^{1-4,10} The experience of these authors, in accordance with Gray and Villar,⁸ suggests that this entity may be more common than previously implied by isolated case reports.

Dislocation can result in numerous causes of persistent pain, including bone fragments, articular fragments, and labral tearing in addition to rupture of the ligamentum teres. Twisting injuries are commonly implicated in labral tears. Thus, little about the history would specifically lead the investigator to suspect

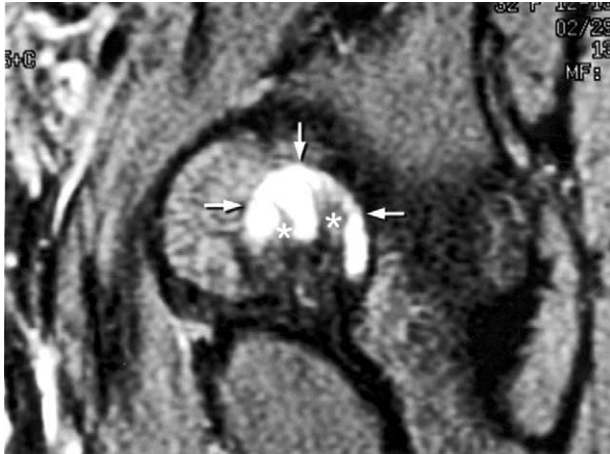


FIGURE 4. MRA of a right hip. Sagittal T1 fat-suppressed image through the acetabular fossa identifies fibers of the ligamentum teres disrupted from its femoral attachment (asterisks) silhouetted by contrast contained within the fossa (arrows).

ligament rupture. The ligament is noted to be taut with flexion, adduction, and external rotation and could reflect a mechanism of twisting injury.⁸ However, Delcamp et al.¹ described hyperabduction as a mechanism of rupture and, in the present study, we were unsuccessful in identifying a specific type of twisting pattern. Also, the characteristic symptoms, including catching, popping, locking, and giving way are non-specific for a variety of intra-articular lesions.

No examination finding would distinguish injury to the ligament. Log rolling of the hip back and forth is generally considered to be the most specific examination maneuver for intra-articular hip pathology because it rotates the femoral head back and forth in relation to the acetabulum and capsule, not stressing any of the surrounding extra-articular structures.¹⁵ Forced flexion combined with internal rotation is a more sensitive test for hip joint pain but may normally cause some discomfort. Both of these observations are generally supported by the results in this study. However, neither of these examination findings are specific for pathology of the ligamentum teres. They are simply useful in trying to determine an intra-articular origin of the patient's symptoms.

Historically, investigative studies have been useful in discerning only the most obvious forms of hip pathology such as bony loose bodies, avascular necrosis, and degenerative disease. As arthroscopy began to discern the nature and prevalence of various intra-articular disorders, advances in imaging technology have followed. Current emphasis has been on high-resolution MRI and combined gadolinium arthrogra-

phy techniques. The most significant advances have been in interpreting labral lesions.^{16,17} As the ligamentum teres is scrutinized more, sensitivity for detecting injury to this structure will probably improve. Currently, it is best recognized only if an accompanying avulsed bony fragment is present. From this study, only 2 ruptures were identified preoperatively, both by MRA.

When diagnosed at arthroscopy, rupture of the ligamentum teres can be effectively addressed. Technical points that facilitate debridement include enlarged capsular incisions to improve maneuverability within the joint; curved shaver blades to facilitate access medially over the femoral head; use of a 3-portal technique, and intraoperative rotation of the joint.

We believe that debridement should be limited to only the disrupted fibers, and indiscriminate resection should be avoided. We recognize that the central artery of the ligamentum teres remains patent in a variable portion of adults.^{18,19} Exactly how important this is to the vascularity of the femoral head is unknown, but the concern would be whether debridement of a healthy ligament and disruption of this vessel might potentiate avascular necrosis. No evidence that the ligament contributes significantly to stability of the hip joint has been found, but it likely has other important functions that have yet to be fully elucidated, such as joint proprioception and nociception and a proposed role spreading synovial fluid across the articular surfaces via a windshield wiper effect.⁸

A potentially confounding variable in this study is the presence of coexistent pathology in 15 cases. However, as noted in the results, no statistical difference was seen between those with and without associated pathology. The average improvement was 44 points for isolated lesions and 42 points for cases with accompanying damage. These results are superior to any previously published for the various types of associated pathology. Thus, the suggestion that simply addressing the coexistent lesions could explain the outcomes reported here seems unlikely.

According to this study, regardless of the cause and often regardless of the associated pathology, hip problems in which disruption of the ligamentum teres is implicated as a contributing source may respond well to arthroscopic intervention. We are just beginning to recognize the extent of this entity. Its long-term consequences and potential consequences of treatment remain to be defined.

In conclusion, rupture of the ligamentum teres is an increasingly recognized cause of persistent hip pain after injury. The extent of trauma is variable and may

occur with or without dislocation of the joint. This entity should be considered in the differential diagnosis of any case of intractable pain after injury. These preliminary results suggest that arthroscopy can be quite effective in the management of these lesions.

REFERENCES

1. Delcamp DD, Klarren HE, VanMeerdervoort HFP. Traumatic avulsion of the ligamentum teres without dislocation of the hip. *J Bone Joint Surg Am* 1988;70:933-935.
2. Barrett IR, Goldberg JA. Avulsion fracture of the ligamentum teres in a child: A case report. *J Bone Joint Surg Am* 1989; 71:438-439.
3. Glynn TP Jr, Kreipke DL, DeRosa GP. Computed tomography arthrography in traumatic hip dislocation. *Skeletal Radiol* 1989;18:29-31.
4. Ebraheim NA, Savolaine ER, Fenton PJ, Jackson WT. A calcified ligamentum teres mimicking entrapped intraarticular bony fragments in a patient with acetabular fracture. *J Orthop Trauma* 1991;5:376-378.
5. Byrd JWT. Hip arthroscopy utilizing the supine position. *Arthroscopy* 1994;10:275-280.
6. Sampson TG, Glick JM. Indications and surgical treatment of hip pathology. In: McGinty J, Caspari R, Jackson R, Poehling G, eds. *Operative arthroscopy*. Ed 2. New York: Raven Press, 1995;1067-1078.
7. McCarthy JC, Day B, Busconi B. Hip arthroscopy: applications and technique. *J Am Acad Orthop Surg* 1995;3:115-122.
8. Gray AJR, Villar RN. The ligamentum teres of the hip: an arthroscopic classification of its pathology. *Arthroscopy* 1997; 13:575-578.
9. Byrd JWT. Indications and contraindications. In: Byrd JWT, ed. *Operative hip arthroscopy*. New York: Thieme, 1998;7-24.
10. Kashiwagi N, Suzuki S, Seto Y. Arthroscopic treatment for traumatic hip dislocation with avulsion fracture of the ligamentum teres. *Arthroscopy* 2001;17:67-69.
11. Byrd JWT, Jones KS. Hip arthroscopy in athletes. *Clin Sports Med* 2001;20:749-762.
12. Byrd JWT, Jones KS. Prospective analysis of hip arthroscopy. *Arthroscopy* 2000;16:578-587.
13. Byrd JWT. The supine position. In: Byrd JWT, ed. *Operative hip arthroscopy*. New York: Thieme, 1998;123-138.
14. Keene GS, Villar RN. Arthroscopic anatomy of the hip: An in vivo study. *Arthroscopy* 1994;10:392-399.
15. Byrd JWT. Investigation of the symptomatic hip: Physical examination. In: Byrd JWT, ed. *Operative hip arthroscopy*. New York: Thieme, 1998;25-41.
16. Czerny C, Hofmann S, Neuhold A, et al. Lesions of the acetabular labrum: Accuracy of MR imaging and MR arthrography in detection and staging. *Radiology* 1996;200:225-230.
17. Petersilge CA, Haque MA, Petersilge WJ, et al. Acetabular labral tears: Evaluation with MR arthrography. *Radiology* 1996;200:231-235.
18. Howe WW Jr, Lacey T II, Schwartz RP. A study of the gross anatomy of the arteries supplying the proximal portion of the femur and the acetabulum. *J Bone Joint Surg Am* 1950;32: 856-866.
19. Wertheimer LG, Lopes SDF. Arterial supply of the femoral head, a combined angiographic and histological study. *J Bone Joint Surg Br* 1953;35:442-461.